

# Raptorial jaws in the throat help moray eels swallow large prey

Rita S. Mehta<sup>1</sup> & Peter C. Wainwright<sup>1</sup>

Most bony fishes rely on suction mechanisms to capture and transport prey<sup>1</sup>. Once captured, prey are carried by water movement inside the oral cavity to a second set of jaws in the throat, the pharyngeal jaws, which manipulate the prey and assist in swallowing<sup>1,2</sup>. Moray eels display much less effective suction-feeding abilities<sup>3</sup>. Given this reduction in a feeding mechanism that is widespread and highly conserved in aquatic vertebrates, it is not known how moray eels swallow large fish and cephalopods<sup>4–7</sup>. Here we show that the moray eel (*Muraena retifera*) overcomes reduced suction capacity by launching raptorial pharyngeal jaws out of its throat and into its oral cavity, where the jaws grasp the struggling prey animal and transport it back to the throat and into the oesophagus. This is the first described case of a vertebrate using a second set of jaws to both restrain and transport prey, and is the only alternative to the hydraulic prey transport reported in teleost fishes. The extreme mobility of the moray pharyngeal jaws is made possible by elongation of the muscles that control the jaws<sup>8</sup>, coupled with reduction of adjacent gill-arch structures<sup>9</sup>. The discovery that pharyngeal jaws can reach up from behind the skull to grasp prey in the oral jaws reveals a major innovation that may have contributed to the success of moray eels as apex predators hunting within the complex matrix of coral reefs<sup>10,11</sup>. This alternative prey transport mode is mechanically similar to the ratcheting mechanisms used in snakes<sup>12,13</sup>—a group of terrestrial vertebrates that share striking morphological, behavioural<sup>14</sup> and ecological convergence with moray eels.

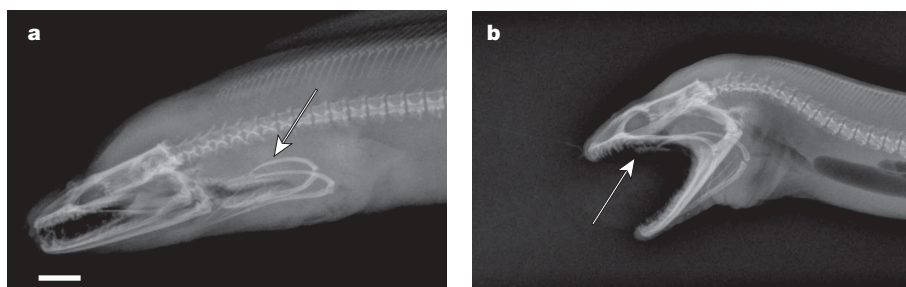
Anguilliform fishes, collectively known as eels, are characterized by an elongate body, a small cross-sectional area and an absence of pelvic fins<sup>15</sup>. These characteristics enable eels to live in confined spaces, promoting reclusive and enigmatic lifestyles<sup>10,16</sup>. Within the Anguilliformes, moray eels (Muraenidae) are a monophyletic group of predators that occupy coral crevices of shallow reefs<sup>10,11,16</sup>. Despite high species richness (roughly 200 species constitute approximately one-quarter of eel diversity worldwide<sup>11</sup>) and their role as top predators of many coral reef ecosystems<sup>7,17,18</sup>, the mechanisms of feeding in morays are poorly understood, particularly with respect to the large prey they are known to eat<sup>4–7</sup>. Given the striking morphological and ecological features of morays,

understanding the basis of their feeding performance may provide insight into their successful radiation on coral reefs.

In a recent study, we described the feeding kinematics of two moray species with diverse dietary habits, calling attention to the marked reduction of important suction-producing cranial elements, particularly the hyoid skeleton and sternohyoideus muscle<sup>3</sup>. From kinematic analysis of feeding behaviour, we concluded that morays do not use suction to capture prey but, rather, apprehend prey by biting. Biting and suction are not mutually exclusive mechanisms<sup>19</sup>. Among ray-finned fishes, the use of a suction-induced flow of water is the only known mechanism for transporting prey from the oral jaws to the pharyngeal jaws and oesophagus<sup>1,20</sup>.

Morays have a well-developed pharyngeal jaw apparatus that is positioned posterior to the skull—a more caudal position compared to the pharyngeal jaws of other teleosts<sup>9,21</sup> (Fig. 1a). In light of their reduced capacity to suction water with their jaws, we explored the possibility that morays have evolved an alternative to hydraulic-based prey transport to move large prey from the oral jaws to the pharyngeal jaws, a distance that is secondarily elongate in morays<sup>9</sup>.

We used high-speed video to study intra-oral transport behaviour in reticulated morays, *M. retifera*. In each feeding sequence, once the prey was captured in the oral jaws, morays protracted their pharyngeal jaws forward to ensnare the prey, which was then pulled into the moray's throat (see Supplementary Movies 1 and 2). In 40 intra-oral transport sequences, morays protracted their pharyngeal jaws into the oral cavity 88% of the time. Pharyngeal jaw protraction extended as far as the anterior margin of the orbit, a total of 3.5 cm in an eel with a total head length of 3.3 cm (Fig. 1b). In the remaining four trials, we observed anterior–posterior movement of the gill-arch area, but the pharyngeal jaws did not extend past the corner of the mouth. When the pharyngeal jaws engage the prey item, morays increase their oral jaw gape, releasing the prey and extend their head forward while the pharyngeal jaws retract, dragging the prey into the oesophagus (Fig. 2). This mechanism of prey transport is behaviourally and functionally convergent to prey transport in snakes. Snakes transport prey by alternating ratcheting movements of the left and right sides of their upper jaws to advance their head over prey<sup>12,13</sup>.



**Figure 1 | Radiographs in left lateral view depicting the extreme positions of the pharyngeal jaws in *M. retifera* during prey transport. a**, Posterior placement of the pharyngeal jaws in relation to the skull. The arrow points to the pharyngeal jaws. **b**, Pharyngeal jaws in their protracted position. The arrow points to the upper pharyngobranchial. Scale bar for **a** and **b**, 1 cm.

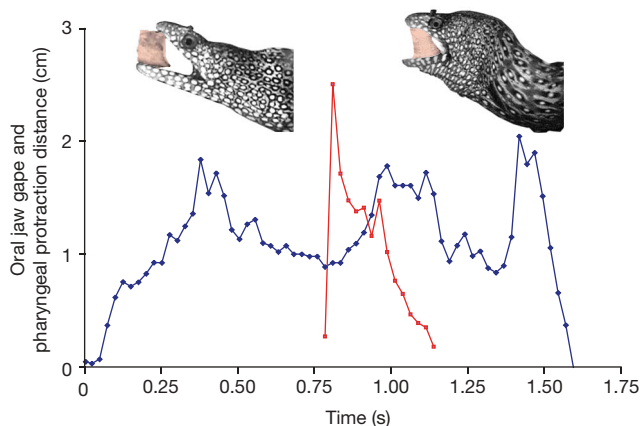
<sup>1</sup>Section of Evolution and Ecology, University of California, One Shields Avenue, Davis, California 95616, USA.

Oral jaw ratcheting is coupled with flexion and extension of their cervical and thoracic vertebrae<sup>13</sup>. Ratcheting enables snakes to maintain a bite on their prey with one side of their upper jaws while the opposing side moves over the prey. Morays transport prey using alternating movements of the oral and pharyngeal jaws followed by flexion and extension of the anterior region of the vertebral column. The dual-jaw system of morays functions to alternate oral biting with pharyngeal biting, allowing morays to maintain a grip on their prey at all times, as snakes do.

Pharyngeal jaws are modified gill arches that are bilaterally paired<sup>2,22</sup>. In many teleost fishes, the upper pharyngeal jaws are broad plates. Both upper and lower pharyngeal jaws bear teeth. The lower pharyngeal jaws press against the upper pharyngeal jaws while the latter are moved posteriorly in a shearing motion to manipulate material that is transported into the throat, a function that is relatively conserved across bony fish<sup>2,23</sup>. The upper and lower pharyngeal jaws of *M. retifera* are not broad structures, but rather elongate, thin, grasping arms. The upper arms are formed by the fourth epibranchials and the lower are formed by the fourth ceratobranchials. The upper and lower jaws bear sharp recurved teeth, giving the impression of talons (Fig. 3a, b). A hinge, which attaches the upper pharyngobranchial to the epibranchial, enables the toothed pharyngobranchial to rotate dorsally. The upper jaws have slight independent anterior–posterior-directed movement and greater lateral movement. The left and right sides of the lower pharyngobranchials are joined anteriorly by a region of connective tissue fibres and are restricted to anterior–posterior-directed movement. The design of the moray pharyngeal jaw represents specialization for extreme transport movements to carry prey from the oral jaws into the oesophagus.

In most groups of bony fishes, the pharyngeal jaws are suspended from the neurocranium, just posterior to the orbit and rostral to the oesophagus. The jaws are further bracketed anteriorly by the first to third gill-arch elements and posteriorly and ventrally by the pectoral girdle. These larger skeletal elements surrounding the pharyngeal apparatus stabilize and limit pharyngeal motion, which is powered by short protractor and retractor muscles<sup>2</sup>. The extreme range of pharyngeal jaw motion in *M. retifera* is made possible by elongation of the pharyngeal muscles and reduction in the anterior branchial elements that constrain the pharyngeal movements in other bony fish.

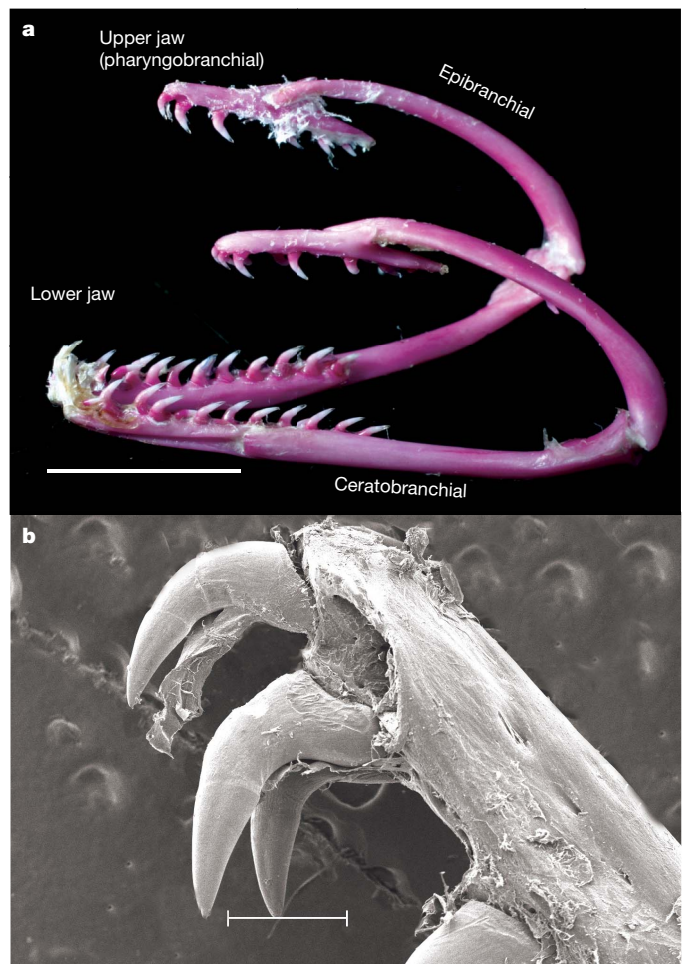
A videofluoroscopy sequence coupled with anatomic dissections revealed the pharyngeal jaws in their full range of motion and enabled



**Figure 2 | The oral gape cycle in relation to the pharyngeal jaw cycle in *M. retifera*.** After peak oral gape (blue trace), oral jaws make contact with the prey (pink rectangle) by biting. Pharyngeal jaws (red trace) are fully protracted and the recurved teeth on the upper pharyngeal teeth are in contact with the prey. Pharyngeal jaws grip prey and begin retracting prey towards the oesophagus. Prey is pulled into the oesophagus as the moray extends its neurocranium forward and advances its body over the prey while increasing its oral gape, similar to a snake.

us to provide a description of pharyngeal jaw protraction and retraction (Fig. 4a–c). Upper pharyngeal jaw protraction is presumably caused by contraction of the levator externi and interni muscles, which originate on the parasphenoid. The levator externus inserts on the dorsal side of the fourth epibranchial arm. The levator internus muscle inserts on the dorsal side of the upper pharyngobranchial. Contraction will result in dorsal rotation of the pharyngobranchial, which positions the recurved teeth to snag prey on contact. The lower pharyngeal jaws are protracted by the rectus communis, which originates on the ventral side of the hyoid arch and attaches onto the anteroventral margin of the lower pharyngeal jaw. Throughout pharyngeal protraction, the epibranchial and ceratobranchial arms are adducted by contraction of a well-developed adductor muscle that originates on the dorsal epibranchial and inserts onto the lateral side of the ceratobranchial. Adduction of the pharyngeal arms compresses the pharyngeal jaw apparatus, facilitating smooth movement through the pharynx. As the pharyngeal jaw enters the oral cavity the distance between the upper and lower pharyngeal teeth widens owing to further protraction of the upper and lower jaw and relaxation of the adductor.

Once the teeth of the upper jaw ensnare the prey, a dorsal retractor and the pharyngocleithralis retract the pharyngeal jaw. The dorsal retractor originates on the vertebral column (around vertebrae 15 in *M. retifera*) and inserts on the most posterior end of the epibranchial arm. The pharyngocleithralis originates on the cleithrum and inserts onto a lateral groove on the lower pharyngeal



**Figure 3 | Detailed anatomy of the pharyngeal jaw apparatus in *M. retifera*.** **a**, Left lateral view of a cleared and alizarin red-stained pharyngeal jaw apparatus, illustrating the sharp, recurved teeth on the pharyngobranchials used to grasp prey. Scale bar, 1 cm. **b**, Left anterior upper pharyngobranchial revealing highly recurved teeth. Scale bar, 500  $\mu$ m.

jaw. The recurved teeth on the lower pharyngeal jaw ensnare prey during retraction rather than protraction. During retraction, the pharyngeal arms adduct so that the upper and lower teeth securely bite down on the prey. With a firm grip on the prey, the pharyngeal jaws travel back to their resting position behind the skull. The prey is further transported into the oesophagus by contraction of the oesophageal sphincter followed by bilateral compression of the body, resulting in posterior-directed waves. Whereas *M. retifera* transported short squid pieces using a single oral–pharyngeal protraction/retraction cycle, long prey (roughly 5 cm in length) were transported using 3–5 cycles (see Supplementary Movie 3). Once the prey had completely entered the oral cavity and could not be grasped by the oral jaws, only pharyngeal and cervical vertebral movements were used to swallow prey.

There are advantages to using a mechanical transport system rather than a hydraulic mechanism to pull prey into the oesophagus. Morays hunt in rocky crevices<sup>4,7,10,11</sup> and these confined spaces may limit the cranial expansion required to generate intra-oral water movement. Both suction feeding and hydraulic transport mechanisms require rapid rotation and abduction of many cranial elements<sup>20,24</sup>. The angular excursion of cranial movements scales with body size, and maximum excursion velocities and overall timing of mouth opening increases during suction feeding<sup>25</sup>. Thus, cranial movements may be limited and less effective for large predatory fish hunting in the confines of coral crevices. Small prey are easily captured with suction, whereas large prey may escape the flow field in

front of a moray's mouth<sup>26</sup>. Large morays with their well-developed jaw-closing muscles and sharp teeth can potentially generate much greater forces with a bite than with hydrodynamic forces<sup>27</sup>. Also, teeth in the oral jaws can restrain the prey even if only in contact with a small portion of the prey. As long as the moray can sink a few teeth into its prey, the pharyngeal jaws can protract to deliver a second bite.

Although the 45,000 species of vertebrates exhibit great diversity in feeding mechanisms, very few transport behaviours exist. Hydraulic, lingual and inertial transport behaviours are widespread and have evolved independently numerous times across vertebrate lineages<sup>28</sup>. A fourth mechanism, ratcheting (gnathic transport), occurs in snakes and exhibits remarkable similarities to moray transport behaviour in which the oral and pharyngeal jaws alternate to pull prey into the oesophagus. The independent evolution of ratcheting mechanisms enables both morays and snakes to maintain a constant grip on their prey. The ability of morays and snakes to circumvent gape constraints that are magnified by their convergent elongate and limbless body plan may be independently correlated with analogous innovations of their feeding apparatus.

Pharyngeal jaws are a complex musculoskeletal system and a major innovation that increases the range of trophic specializations for feeding in teleosts<sup>2,29</sup>. The evolution of the newly discovered function and design of this widespread jaw system adds to our general understanding of how innovations arise and how they correlate with a particular body plan. Our discovery demonstrates that striking functional novelties can arise with only subtle modifications in existing systems, and offers new insights into the functional morphology of a successful radiation of predatory fish, the moray eels.

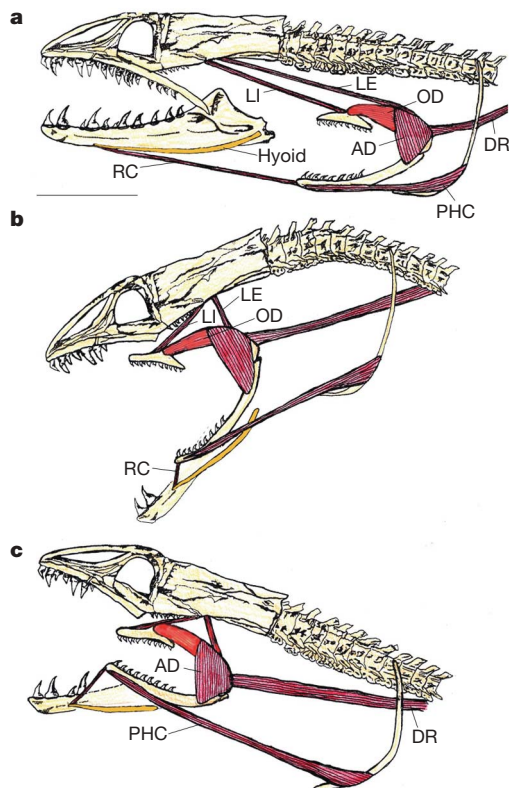
## METHODS SUMMARY

Individuals of *M. retifera* were filmed in 100-litre aquaria at the University of California at Davis (UCD) using a NAC Memrecam ci digital system. Videofluoroscopy was performed on a single specimen at the Center for Imaging Sciences at the School of Veterinary Medicine, UCD. After feeding trials were obtained, freshly killed specimens were radiographed; they were then fixed in 10% formalin and stored in 70% ethanol for dissections, whole-mount clearing and double-staining<sup>30</sup>. The tooth morphology of the pharyngeal jaws was examined with a scanning electron microscope at the Electron Microscopy Laboratory, Department of Medical Pathology and Laboratory Medicine, School of Medicine, UCD.

**Full Methods** and any associated references are available in the online version of the paper at [www.nature.com/nature](http://www.nature.com/nature).

Received 26 March; accepted 3 July 2007.

- Lauder, G. V. in *Fish Biomechanics* (eds Webb, P. W. & Weihs, D.) 280–311 (Praeger, New York, 1983).
- Wainwright, P. C. in *Fish Biomechanics* (eds Shadwick, R. & Lauder, G. V.) 77–101 (Academic, New York, 2006).
- Mehta, R. M. & Wainwright, P. C. Biting releases constraints on moray eel feeding kinematics. *J. Exp. Biol.* **210**, 495–505 (2007).
- Randall, J. E. Food habits of reef fishes of the West Indies. *Stud. Trop. Oceanogr.* **5**, 655–847 (1967).
- Young, R. F. & Winn, H. E. Activity patterns, diet, and shelter site use for two species of moray eels, *Gymnothorax moringa* and *Gymnothorax vicinus*, in Belize. *Copeia* **2003**, 44–55 (2003).
- Yukihira, H., Shibuno, T., Hashimoto, H. & Gushima, K. Feeding habits of moray eels (Pisces: Muraenidae) at Kuchierabu-ji. *Appl. Biol. Sci.* **33**, 159–166 (1994).
- Parrish, J. D. *et al.* Piscivory in a coral reef fish community. *Environ. Biol. Fish.* **14**, 285–297 (1986).
- Nelson, G. J. Branchial muscles in representatives of five eel families. *Pacif. Sci.* **21**, 348–363 (1967).
- Nelson, G. J. Gill arches of Teleostean fishes of the Order Anguilliformes. *Pacif. Sci.* **20**, 391–408 (1966).
- Abrams, R. W., Abrams, M. D. & Schein, M. W. Diurnal observations on the behavioral ecology of *Gymnothorax moringa* (Cuvier) and *Muraena miliaris* (Kaup) on a Caribbean coral reef. *Coral Reefs* **1**, 185–192 (1983).
- Böhlke, E. B., McCosker, J. E. & Böhlke, J. E. in *Fishes of the Western North Atlantic* (ed. Böhlke, E. B.) 104–206 (Sears Foundation for Marine Research Memoir, Yale Univ., New Haven, Connecticut, 1989).
- Cundall, D. & Greene, H. W. in *Feeding: Form, Function, and Evolution in Tetrapod Vertebrates* (ed. Schwenk, K.) 293–333 (Academic, San Diego, 2000).



**Figure 4 | Functional morphological model of pharyngeal jaw movement in *M. retifera*.** The left dentary has been removed in **a–c**, and the left maxilla has been removed in **b** and **c**. **a**, Pharyngeal jaw apparatus at rest. **b**, Pharyngeal jaw protracted: the levator internus (LI) and levator externus (LE) protract the upper jaw into the oral cavity, whereas the rectus communis (RC) protracts the lower jaw. During protraction, the upper pharyngobranchial is dorsally rotated by contraction of the LI and the obliquus dorsalis (OD). **c**, After prey contact, the adductor (AD) contracts to bring the upper and lower jaws together to deliver a second bite. The dorsal retractor (DR) and pharyngocleithralis (PHC) retract the pharyngeal jaws back to their resting position behind the skull. Scale bar, 1 cm.

13. Kley, N. J. & Brainerd, E. L. Post-cranial prey transport mechanisms in the black pinesnake, *Pituophis melanoleucus lodingi*: an x-ray videographic study. *Zoology* **105**, 153–164 (2002).
14. Miller, T. J. Knotting: a previously undescribed feeding behaviour in Muraenid eels. *Copeia* **1987**, 1055–1057 (1987).
15. Robins, C. R. in *Fishes of the Western North Atlantic* (ed. Böhlke, E. B.) 9–23 (Sears Foundation for Marine Research Memoir, Yale Univ., New Haven, Connecticut, 1989).
16. Gilbert, M., Rasmussen, J. B. & Kramer, D. L. Estimating the density and biomass of moray eels (Muraenidae) using a modified visual census method for hole-dwelling reef fauna. *Environ. Biol. Fish.* **73**, 415–426 (2005).
17. Hixon, M. A. & Beets, J. P. Predation, prey refuges, and the structure of coral-reef fish assemblages. *Ecol. Monogr.* **63**, 77–101 (1993).
18. Carr, M. H. & Hixon, M. A. Predation effects on early post-settlement survivorship of coral-reef fishes. *Mar. Ecol. Prog. Ser.* **124**, 31–42 (1995).
19. Alfaro, M. E., Janovetz, J. & Westneat, M. W. Motor control across trophic strategies: muscle activity of biting and suction feeding fishes. *Am. Zool.* **41**, 1266–1279 (2001).
20. Gillis, G. B. & Lauder, G. V. Kinematics of feeding in bluegill sunfish: is there a general distinction between aquatic capture and transport behaviors? *J. Exp. Biol.* **198**, 709–720 (1995).
21. Popta, C. M.-L. Les arcs branchiaux de quelques Muraenidae. *Ann. Sci. Nat.* **19**, 367–390 (1909).
22. Hulseley, C. D., Fraser, G. J. & Strelman, J. T. Evolution and development of complex biomechanical systems: 300 million years of fish jaws. *Zebrafish* **2**, 243–257 (2005).
23. Lauder, G. V. Functional design and evolution of the pharyngeal jaw apparatus in euteleostean fishes. *Zool. J. Linn. Soc.* **77**, 1–38 (1983).
24. Carroll, A. M., Wainwright, P. C., Huskey, S. H., Collar, D. C. & Turingan, R. G. Morphology predicts suction feeding performance in centrarchid fishes. *J. Exp. Biol.* **207**, 3873–3881 (2004).
25. Richard, B. A. & Wainwright, P. C. Scaling of the feeding mechanism of largemouth bass (*Micropterus salmoides*): kinematics of prey capture. *J. Exp. Biol.* **198**, 419–433 (1995).
26. Day, S. W., Higham, T. E., Cheer, A. Y. & Wainwright, P. C. Spatial and temporal flow patterns during suction feeding of bluegill sunfish (*Lepomis macrochirus*) by Particle Image Velocimetry. *J. Exp. Biol.* **208**, 2661–2671 (2005).
27. Westneat, M. W. Evolution of levers and linkages in the feeding mechanism of fishes. *Integr. Comp. Biol.* **44**, 378–389 (2004).
28. Schwenk, K. in *Feeding: Form, Function and Evolution in Tetrapod Vertebrates* (ed., Schwenk, K.) 21–61 (Academic, San Diego, 2000).
29. Liem, K. F. Evolutionary strategies and morphological innovations: cichlid pharyngeal jaws. *Sys. Zool.* **22**, 425–441 (1973).
30. Dingerkus, G. & Uhler, L. D. Enzyme clearing of alcian blue stained whole small vertebrates for demonstration of cartilage. *Stain Technol.* **52**, 229–232 (1977).

**Supplementary Information** is linked to the online version of the paper at [www.nature.com/nature](http://www.nature.com/nature).

**Acknowledgements** We thank M. E. Alfaro, D. C. Collar, S. W. Day, H. W. Greene, N. J. Kley, A. H. Krakauer, R. D. Mehta, J. T. Redwine, A. Sinsheimer, T. W. Schoener and K. Vanderveen for comments on various drafts of this manuscript. We thank N. J. Kley for discussions regarding prey transport in vertebrates. H. Tran and L. B. Feng provided assistance with video collections. We are grateful to R. E. Pollard, C. Stafford, T. B. Waltzek and E. R. Wisner for help with radiographs and videofluoroscopy. P. Kysar provided technical assistance with scanning electron microscopy. We thank the California Academy of Sciences and the Harvard Museum of Comparative Zoology for specimen loans. Funding was provided by the American Association of University Women and by the National Science Foundation.

**Author Contributions** R.S.M. designed research, performed research and wrote the manuscript. P.C.W. helped design the study, contributed to the interpretation of anatomy and video, and participated in writing the manuscript.

**Author Information** Reprints and permissions information is available at [www.nature.com/reprints](http://www.nature.com/reprints). The authors declare no competing financial interests. Correspondence and requests for materials should be addressed to R.S.M. ([rsmehta@ucdavis.edu](mailto:rsmehta@ucdavis.edu)).

## METHODS

Five adult *M. retifera* (standard lengths 35.5, 37.2, 34.2, 36.6 and 40.3 cm) were obtained commercially. Individuals of *M. retifera* were filmed feeding on pieces of cut squid (*Loligo* sp.). Individuals were housed and filmed at 22–27 °C using a NAC Memrecam ci digital system with illumination from two 600-W flood lights. Video sequences were recorded at 100 images per second. Distances in the images were scaled by recording an image of a ruler placed in the field of view.

After all feeding sequences were obtained, pharyngeal jaw movements were studied using a radiograph/digital fluoroscope (Philips, Omni diagnost Eleva) at the Center for Imaging Sciences at the School of Veterinary Medicine, UCD. A moray was placed in a 40-litre glass aquarium and was filmed at 60 images s<sup>-1</sup> while consuming a single goldfish, *Carassius auratus*, soaked in 60% w/v liquid barium sulphate (Novopaque, LPI Diagnostics). Afterwards, the same moray was killed using tricaine methane sulphonate (MS-222) and immediately prepared for radiographs. Radiographs were taken to show the pharyngeal jaws in lateral view at rest and in the extreme protracted position. To radiograph the pharyngeal jaw in the extreme protracted position, we protracted the pharyngeal jaws of the specimen with forceps. The distance the pharyngeal jaw was protracted was slightly less than we observed in the video sequences.

The remaining specimens were killed by overexposure to MS-222 and were formalin-fixed to examine the anatomy related to the pharyngeal jaw apparatus. All specimens were fixed in buffered 10% formalin and stored in 70% ethanol. Anatomical dissections were performed on three specimens to understand the musculature used for protracting and retracting the pharyngeal jaws. Two specimens were cleared using trypsin and double-stained in alcian blue cartilage stain and alizarin red bone stain<sup>30</sup>. Following staining, a pharyngeal jaw from a single specimen was removed and cleaned using forceps and warm water. We then used a digital Canon EOS camera with a macro lens to take photographs of the pharyngeal jaw.

Tooth morphology of the pharyngeal jaws was examined with a scanning electron microscope (Philips XL30 TMP, FEI Co.) and examined with iTEM Software. Our sample was rinsed in deionized water before dehydration in a graded ethanol series, polished with gold powder, dried and then mounted on aluminium stubs and sputter-coated with gold–palladium.